SWOLLEN OPTIC NERVES: NOW WHAT?

Nate Lighthizer, O.D.

Disclosures

- Aerie Pharmaceuticals
- Alcon
- Biotissue
- Diopsys
- MacuLogix
- Nidek
- Nova Oculus
- Optovue
- Quantel
- Reichert
- RevolutionEHR
- Shire

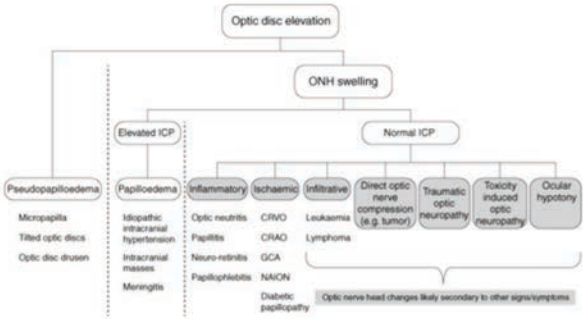

SWELLING VS. PSEUDOSWELLING

- Ways to differentiate:
  1. Direct viewing of the ONH
     - Are the vessels blurred as they cross the disc margin?
     - Is there SVP?

Swelling vs. Pseudoswelling?

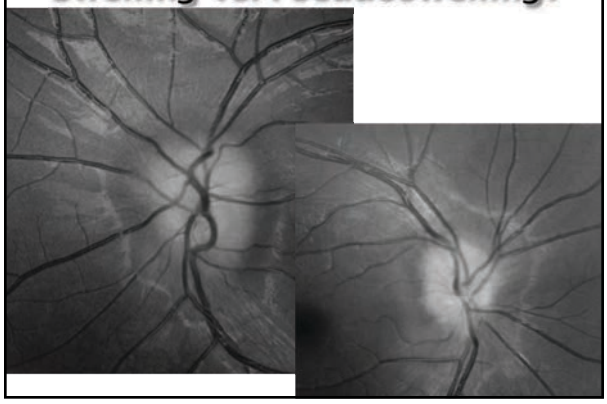

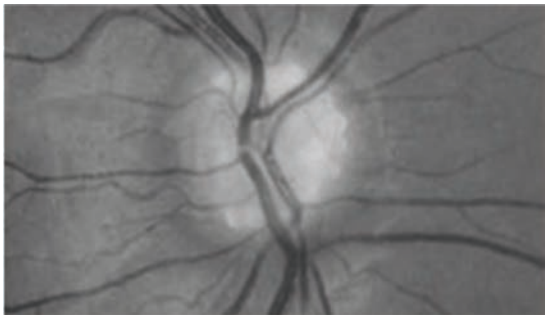

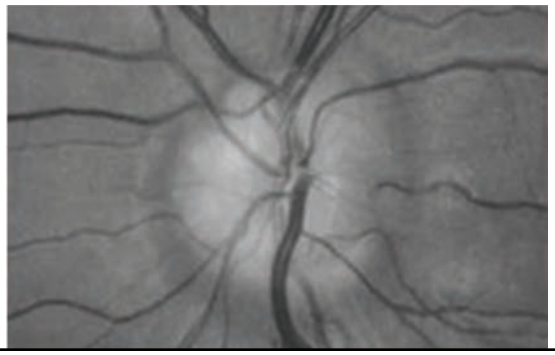

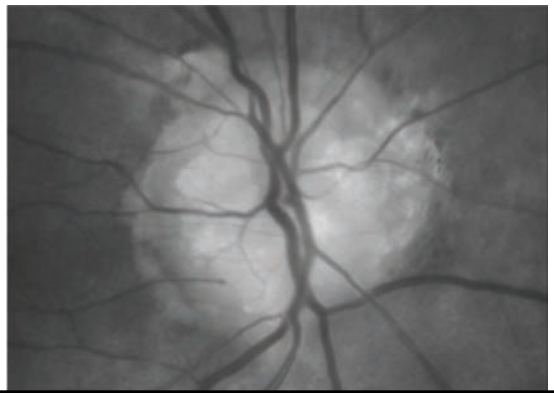

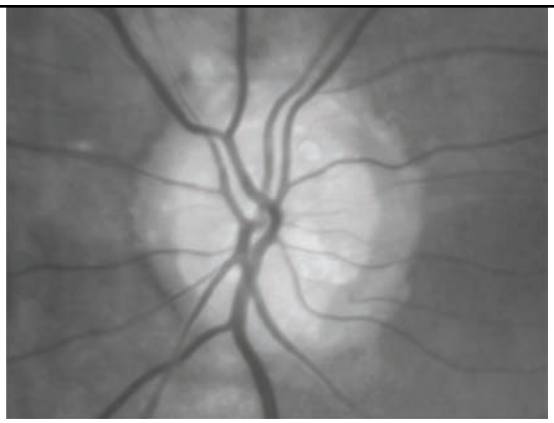

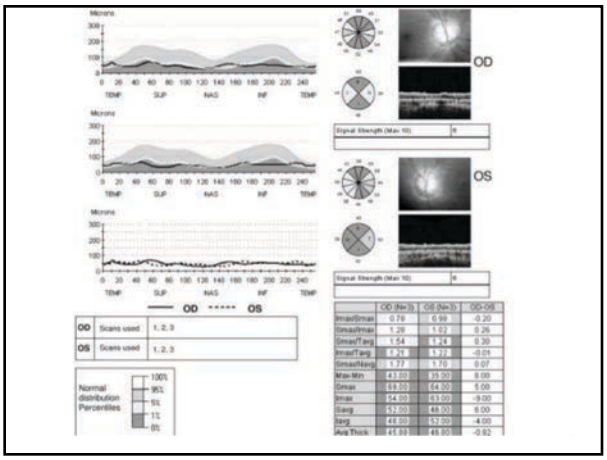
Microns
TEMP
SUP
NAS
INF
TEMP
OD
OS
Signal Strength (Max 10)
OD ----- OS
OD Scans used 1, 2, 3
OS Scans used 1, 2, 3
Normal distribution Percentiles
100%
95%
5%
1%
0%

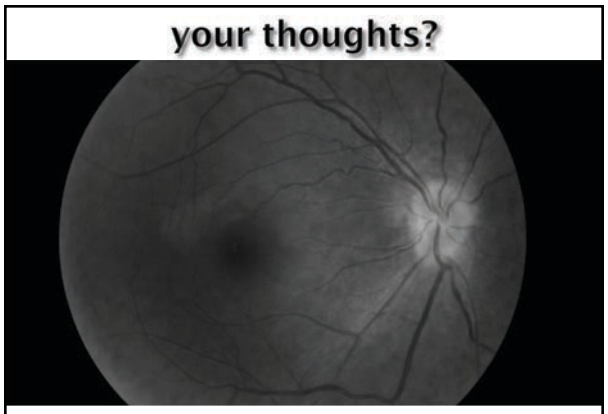
your thoughts?

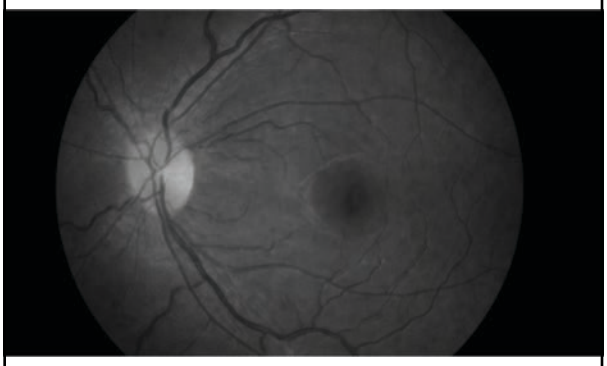

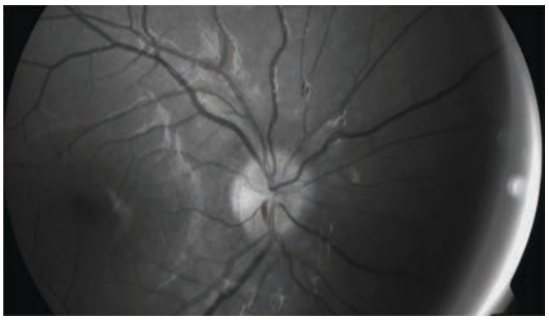

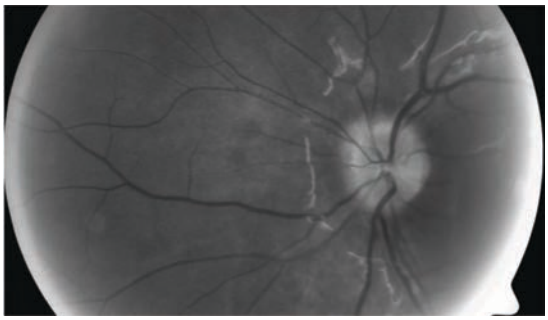

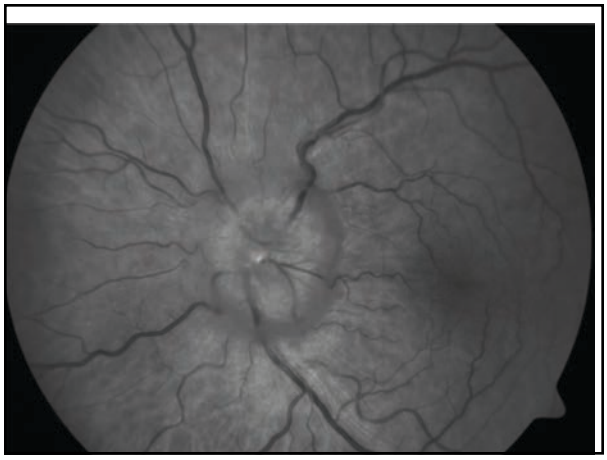

SWELLING VS. PSEUDOSWELLING

- Ways to differentiate:
  1. Direct viewing of the ONH
     - Are the vessels blurred as they cross the disc margin?
     - Is there SVP?
  2. OCT
     - rNFL thickness – normal or elevated or thin?
     - Is there a splitting of retinal layers deep in the retina?

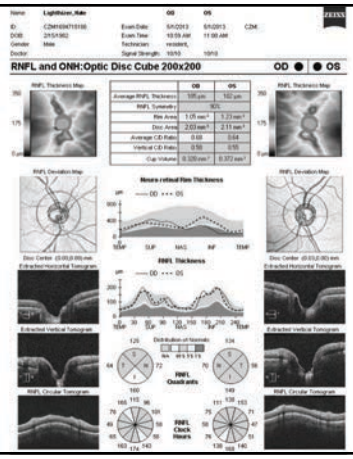

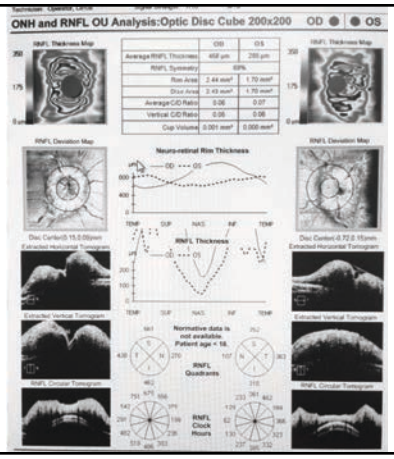

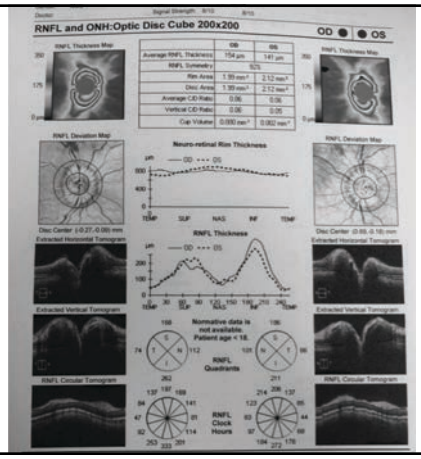
RNFL and ONH:Optic Disc Cube 200x200
OD
OS
Neuro-retinal Rim Thickness
RNFL Thickness
RNFL Quadrants
RNFL Clock Hours

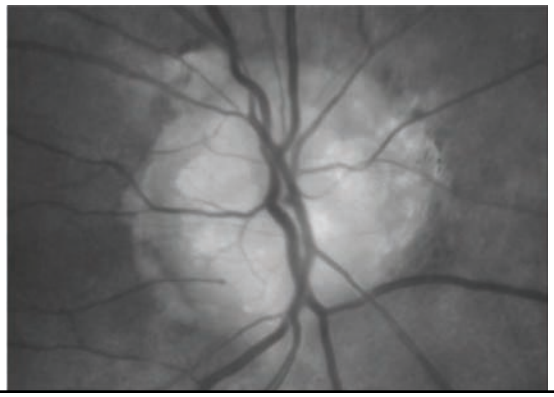

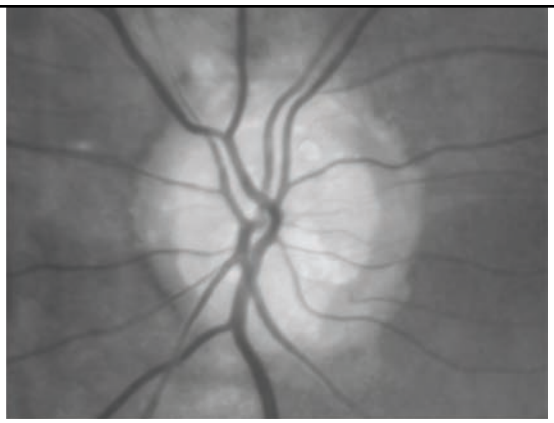

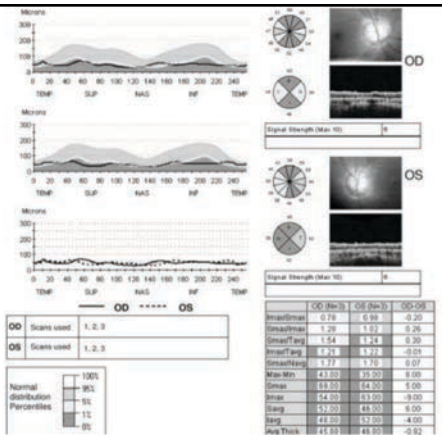
OD
OS

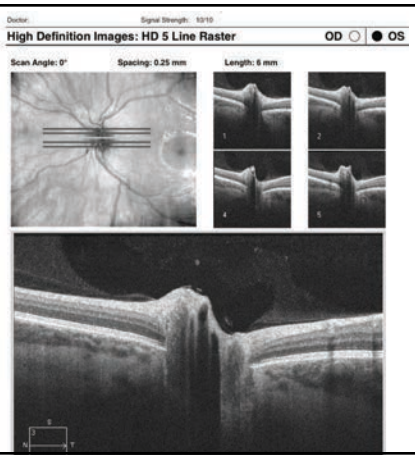
High Definition Images: HD 5 Line Raster
OD
OS
Scan Angle: 0°
Spacing: 0.25 mm
Length: 6 mm

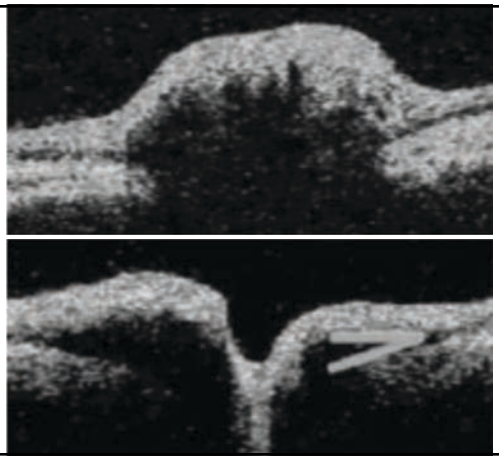

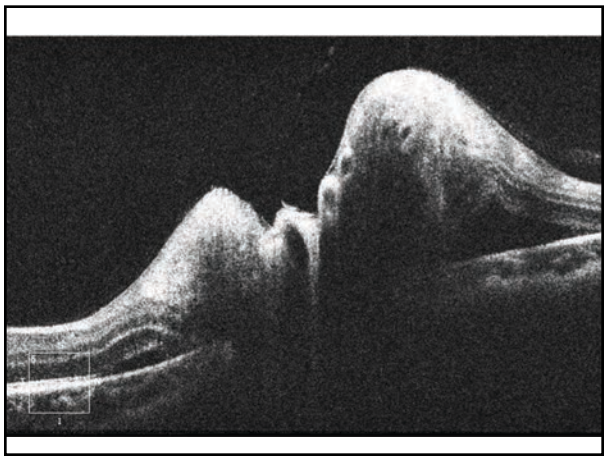

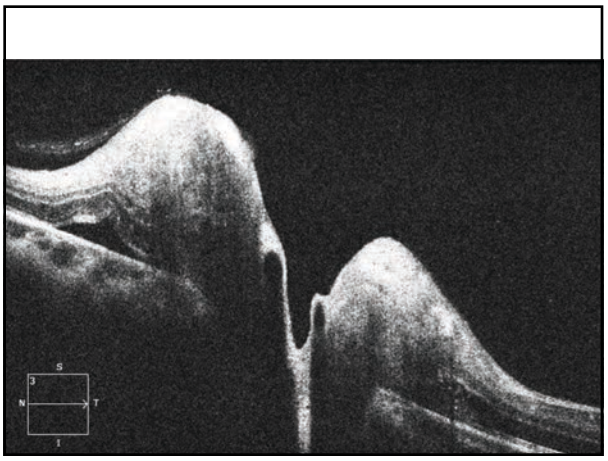

your thoughts?

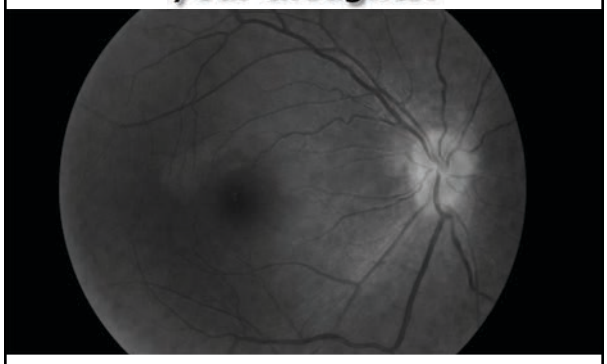

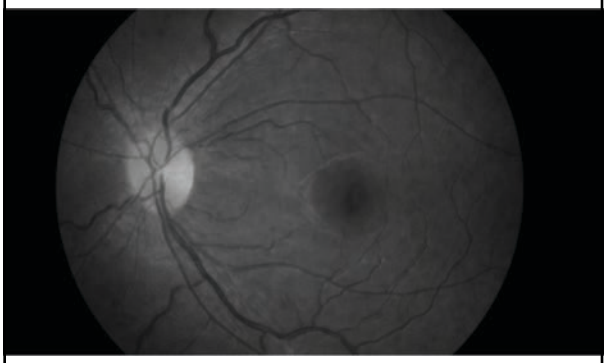

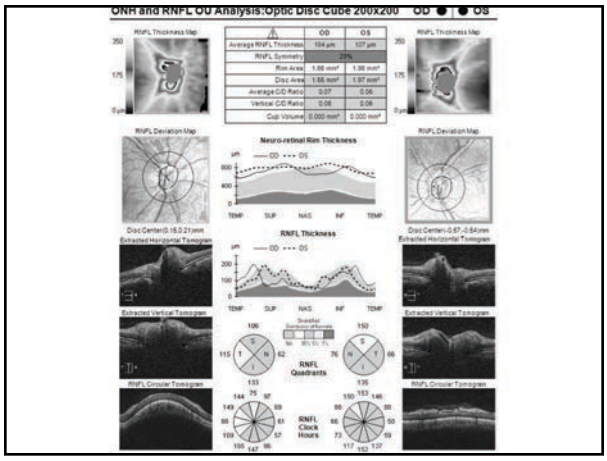

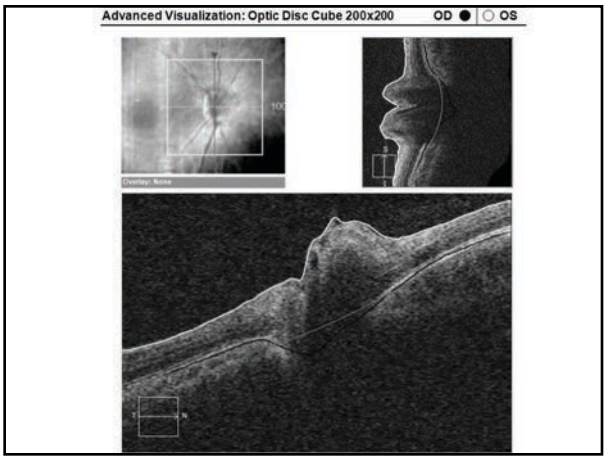

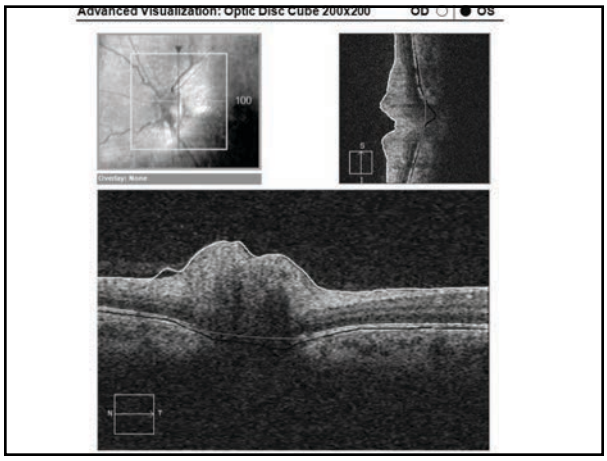

SWELLING VS. PSEUDOSWELLING

- Ways to differentiate:
  1. Direct viewing of the ONH
     - Are the vessels blurred as they cross the disc margin?
     - Is there SVP?
  2. OCT
     - rNFL thickness – normal or elevated?
     - Is there a splitting of retinal layers deep in the retina?
  3. Symptoms?
  4. History?
  5. B-scan
     - Drusen???

Swelling vs. Pseudoswelling?

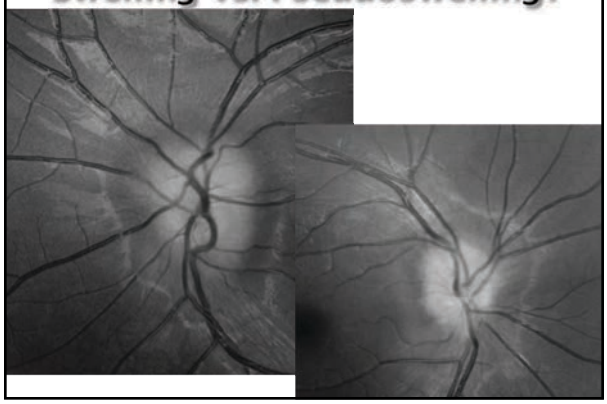

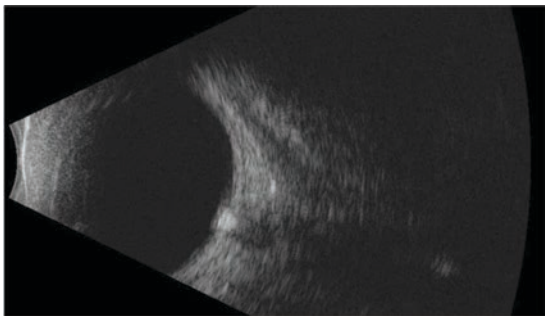

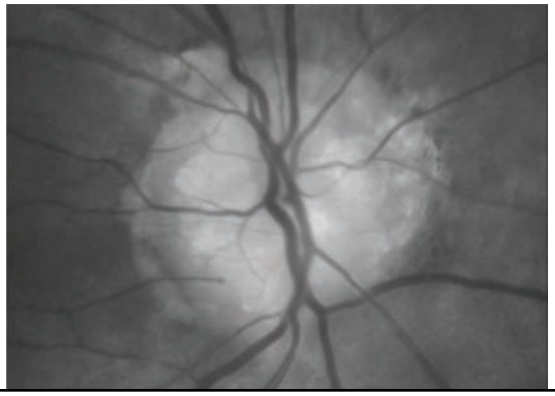

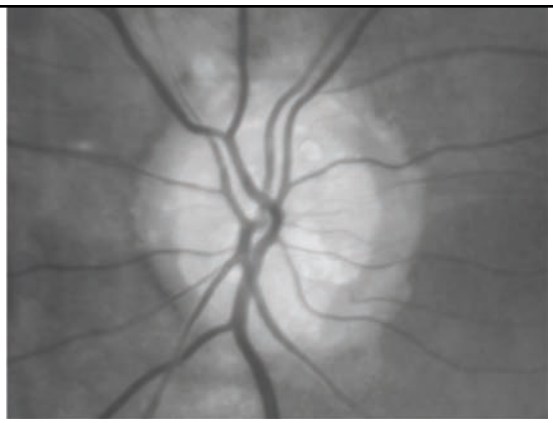

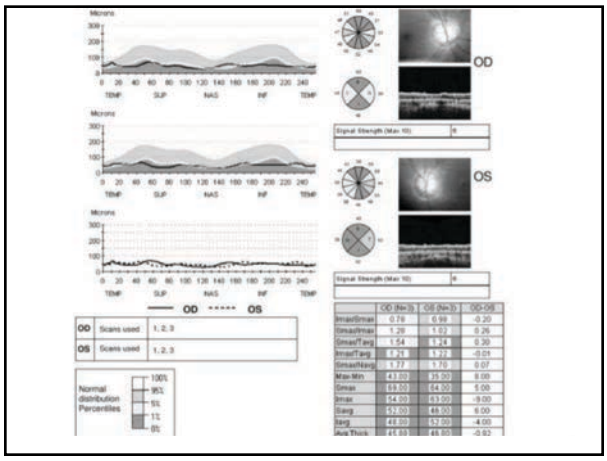

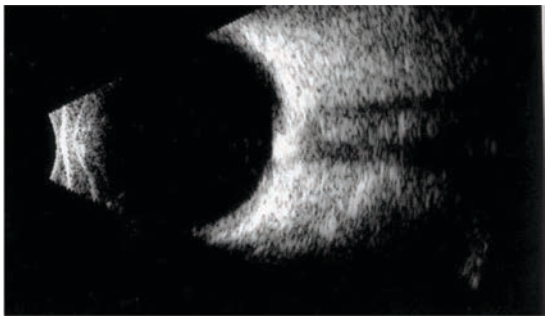

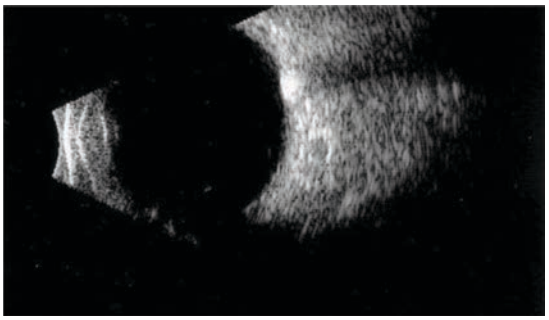

True swelling vs. Psuedoswelling case????

- 12 yoM
- "In for annual eye exam". No complains, concerns or symptoms
- Ocular Hx:
  - Longstanding alternating esotropia
  - +3.25 with mild astigmatism OU
- VA:
  - OD – 20/20
  - OS – 20/20

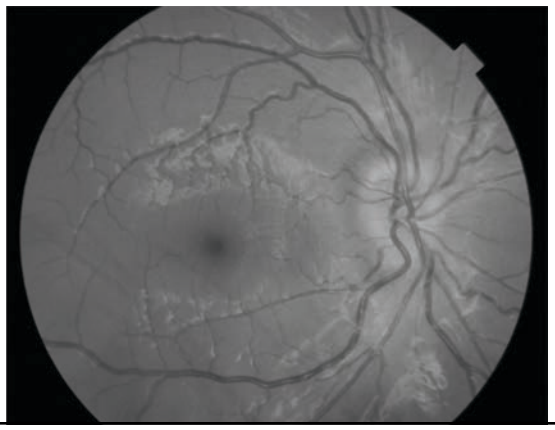

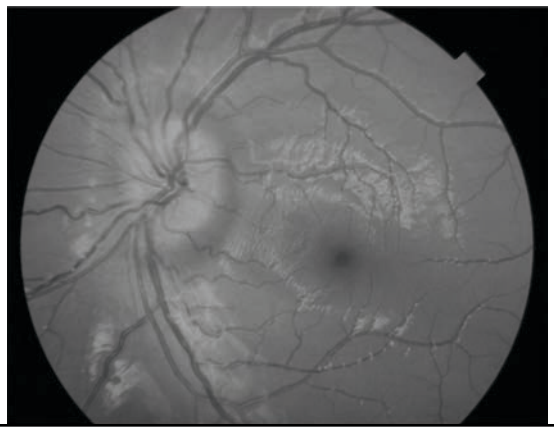

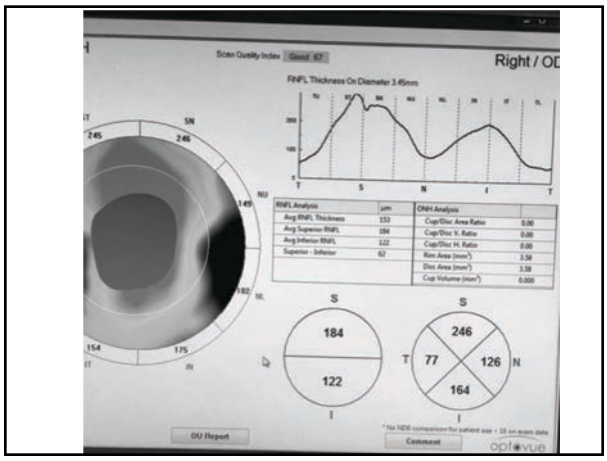

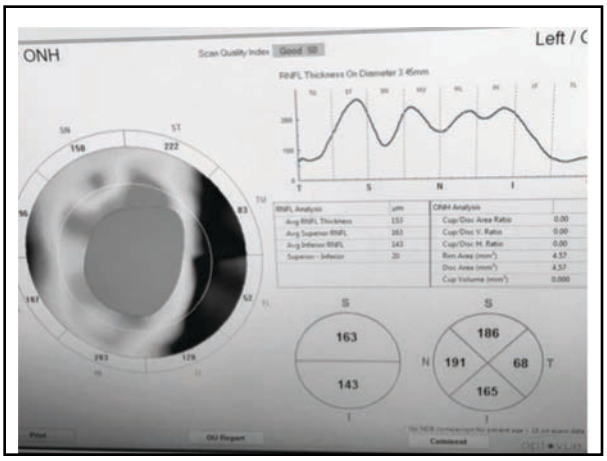

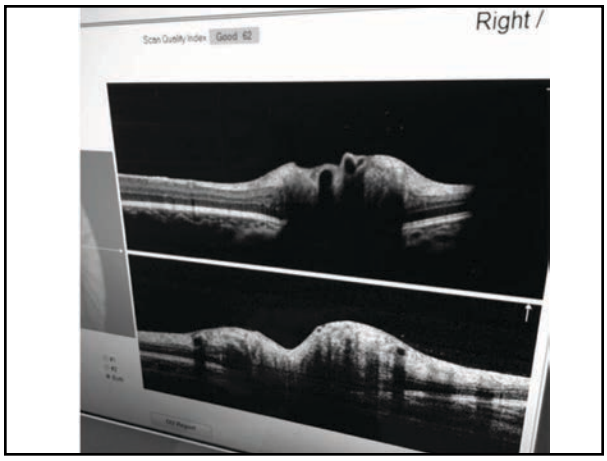

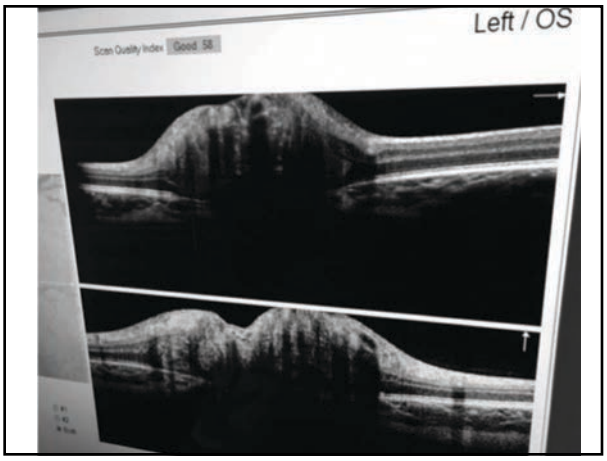

What do you think? Pseudoswelling vs true swelling?

A. Pseudoswelling
B. True swelling

True swelling vs. Psuedoswelling case????

- My recommendation:
  - see a pediatric or neuro-ophthalmologist for a second opinion
  - Not overly concerned
- Pediatric ophthalmologist:
  - Diagnosis:
    - Pseudopapilledema
    - Monitor & see back in 4-6 weeks to monitor for stability

SWELLING VS. PSEUDOSWELLING

- Ways to differentiate:
  1. Direct viewing of the ONH
     - Are the vessels blurred as they cross the disc margin?
     - Is there SVP?
  2. OCT
     - rNFL thickness – normal or elevated?
     - Is there a splitting of retinal layers deep in the retina?
  3. Symptoms?
  4. History?
  5. B-scan
     - Drusen???

Pseudotumor Cerebri

- AKA
  - Idiopathic intracranial hypertension
- Elevated intracranial pressure
  - Not caused by tumor, infection, or obstruction of the ventricular system
  - Increased production vs. decreased absorption
- Etiology:
  - Idiopathic (young, obese females)
  - Medications
    - Oral contraceptives, Tetracyclines, too much vitamin A
  - Trauma

Pseudotumor Cerebri

- Symptoms:
  - HA's (90-98%)
  - Visual disturbances (72%)
    - Transient visual obscurations (TVO's)
  - Tinnitus (20-60%)
  - N&V (30-40%)
  - Diplopia (20-30%)
  - Blurred vision
  - Abnormal color vision - rare

Pseudotumor Cerebri

- Signs
  - Papilledema – hallmark sign of PTC
    - Increased intracranial pressure -> slowing axonal transport -> accumulation of axonal contents in the NFL -> elevated ONH's
    - Bilateral disc edema
    - Blurred disc margins
    - Obscuration of blood vessels*
    - Hyperemia of the disc
    - Venous dilation
    - Peripapillary hemorrhages & CWS
    - Paton's lines

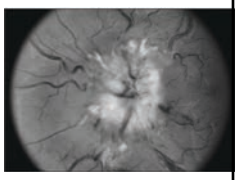

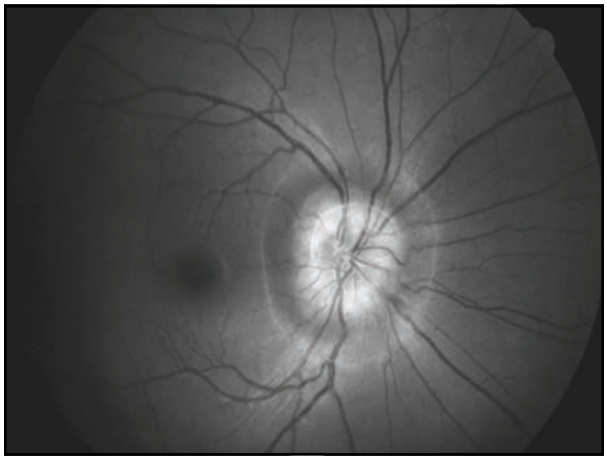

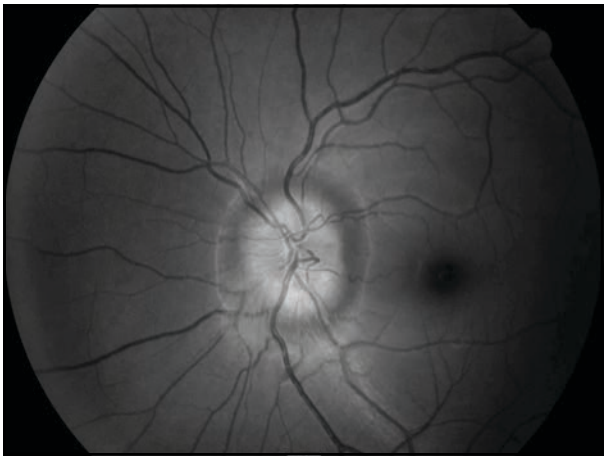

Pseudotumor Cerebri

- Signs
  - Papilledema – hallmark sign of PTC
    - Increased intracranial pressure -> slowing axonal transport -> accumulation of axonal contents in the NFL -> elevated ONH's
    - Bilateral disc edema
    - Blurred disc margins
    - Obscuration of blood vessels*
    - Hyperemia of the disc
    - Venous dilation
    - Peripapillary hemorrhages & CWS
    - Paton's lines

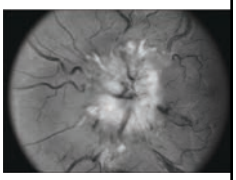

Pseudotumor Cerebri

- Other signs
  - Enlarged blind spot
  - 6th nerve palsy
    - Tends to subside as treatment is effective

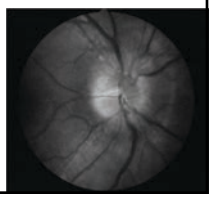

Pseudotumor Cerebri

- Differential Diagnosis:
  - Intracranial tumor/mass
  - Intracranial bleed
  - Hydrocephalus
  - Venous sinus thrombosis
  - IIH

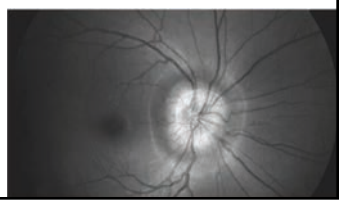

Pseudotumor Cerebri

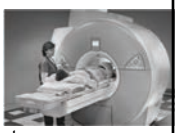

- Diagnosis:
  - Clean MRI/MRV
  - Lumbar puncture
    - Elevated ICP > 250mmH_20 in an obese pt
      > 200mmH_20 in a non-obese pt
    - Normal CSF composition
  - No other neurological findings
    - Exception -> 6th nerve palsy
  - SVP
    - Yes -> not Pseudotumor
    - No -> ?????

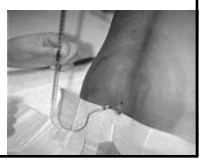

Pseudotumor Cerebri

- Treatment:
  - Weight Loss*
    - Papilledema resolution with weight loss of 6% of total body weight
  - Diamox (acetazolamide)
    - 500 mg Sequels BID-QID
    - Taper as the sx's stabilize
  - Lumbar-peritoneal shunt (CSF shunting)
  - Optic nerve sheath fenestration/decompression

Non-arteritic Ischemic Optic Neuropathy (NAION)

- Lack of perfusion to the ONH or embolic disease that affects the arteries/arterioles that supply the ONH
- Mean age of onset = 61-66 years old
- Associated risk factors:
  - HTN, atherosclerosis, DM, nocturnal hypotension, sleep apnea

Non-arteritic Ischemic Optic Neuropathy (NAION)

- **SYMPTOMS:**
  - Sudden, unilateral, painless loss of vision
  - "I woke up and I can't see out of this one eye"

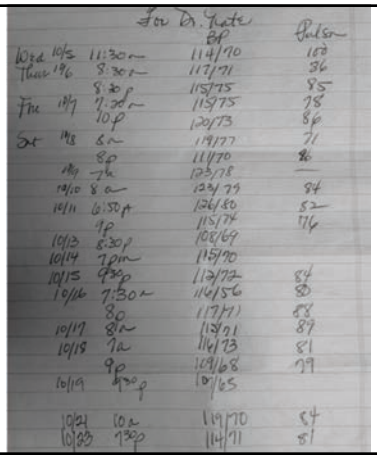

		BP	Pulse
Wed 10/5	11:30a	114/70	100
Thur 10/6	8:30a	117/71	86
	8:30p	115/75	85
Fri 10/7	7:30a	115/75	78
	10p	120/73	86
Sat 10/8	6a	119/77	71
	8p	114/70	86
10/9	7a	123/78	—
10/10	8a	124/79	84
10/11	6:30p	126/80	82
	9p	115/74	76
10/13	8:30p	108/69	
10/14	7pm	115/70	
10/15	9:30p	112/72	84
10/16	7:30a	116/56	80
	8a	117/71	88
10/17	8a	118/71	89
10/18	7a	116/73	81
	9p	109/68	79
10/19	4:30p	107/65	
10/21	10a	119/70	84
10/23	7:30p	114/71	81

Non-arteritic Ischemic Optic Neuropathy (NAION)

- **SIGNS:**
  - Diffuse or segmental disc edema
  - Peripapillary flame-shaped hemes
  - Retinal arterial attentuation

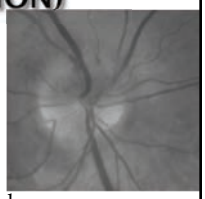

  - (+) APD
  - VF defect – often inferior altitudinal
  - What does the other eye look like?
    - Small nerve?
    - Small cup?

Non-arteritic Ischemic Optic Neuropathy (NAION)

- **DIAGNOSIS:**
  - Normal ESR & CRP
  - (-) symptoms of GCA
- **DIFFERENTIAL DIAGNOSIS:**
  - AAION

Non-arteritic Ischemic Optic Neuropathy (NAION)

- **TREATMENT:**
  - No proven effective treatment

  - Options?
    - Aspirin
    - Lower IOP??
    - Intraocular VEGF treatment

- Prognosis:
  - unilateral.....
  - guarded.....but it depends on many factors

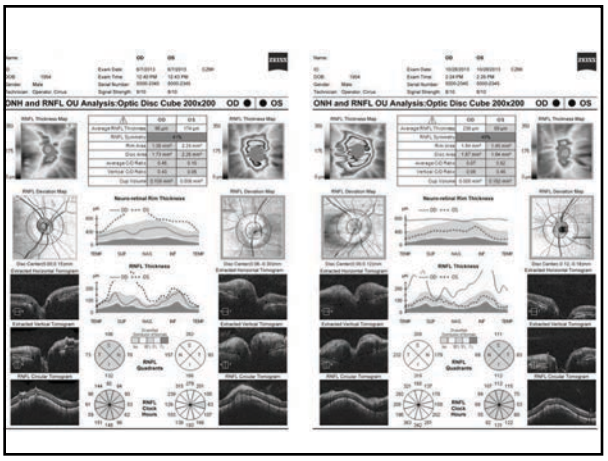

Non-arteritic Ischemic Optic Neuropathy (NAION)

- **TREATMENT:**
  - No proven effective treatment
  - Options?
    - Aspirin
    - Lower IOP??
    - Intraocular VEGF treatment
- Prognosis:
  - unilateral.....
  - guarded.....but it depends on many factors

Giant Cell Arteritis

- Chronic inflammatory disorder affecting the medium-large sized cranial blood vessels
- Inflammatory mediators cause:
  - proliferation, thickening, and fibrosis of vessel walls -> inflammatory occlusion
- Risk factors:
  - Age
  - Females
  - Scandinavian
- Accounts for 6% of ischemic optic neuropathy cases

Giant Cell Arteritis

- Symptoms:
  - New onset HA
  - Jaw claudication
  - Scalp tenderness/pain
  - Flu-like sx's/weight loss
  - Pain and stiffness in the shoulders, hips, torso
    - Polymyalgia Rheumatica (PMR)
  - Sudden, severe, painless vision loss
    - Usually unilateral
  - Diplopia

Giant Cell Arteritis

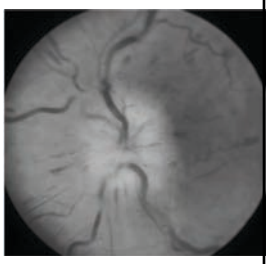

- Signs:
  - Sudden, severe, painless vision loss
  - (+) APD
  - Pale, swollen optic disc
    - Flame shaped hemes
    - CWS's
  - CRAO
  - Ocular ischemic syndrome
  - EOM problems

Giant Cell Arteritis

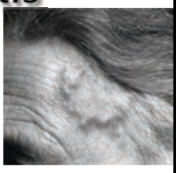

- Diagnosis:
  - Clinical symptoms
  - Prominent temporal artery
  - Lack of temporal artery pulsation
  - CBC with differential & platelets
  - ESR males = age/2 females = (age+10)/2
  - CRP
  - Platelets
  - Temporal artery biopsy

Giant Cell Arteritis

- Treatment:
  - Refer
  - IV and/or oral steroids
    - IV 250 mg i.v. q6h (1g/day) for 3 days and/or
    - Oral 1-2mg/kg/day
  - Baby aspirin
- Prognosis:
  - Extremely poor

Optic Neuritis

- Patient is typically < 45 years old
- Females > males

- **SYMPTOMS:**
  - Acute vision loss – most often unilateral
  - Eye pain in/behind the eye (80-90%)
    - worsens with eye movements

Optic Neuritis

- **SIGNS:**
  - Visible ONH swelling (33%)
  - (+) APD
  - Color vision abnormalities
    - red cap test
  - Brightness reduction
    - brightness comparison test
  - Visual field defect – often central
  - ONH pallor – 4-12 weeks after onset of symptoms

Optic Neuritis

- **DIAGNOSIS:**
  - MRI with gadolinium

Optic Neuritis

- **TREATMENT:**
  - MRI results? Already diagnosed with MS?
  - ONTT (Optic Neuritis Treatment Trial)
    - No oral steroids
    - IV methylprednisolone (1g/day) X 3 days
      - oral steroids (1mg/kg/day) X 10-14 days
      - Taper oral steroids over 4-7 days

Optic Neuritis

- **TREATMENT:**
  - MRI results? Already diagnosed with MS?
  - Controlled High-Risk Subjects Avonex MS Prevention Study (CHAMPS)
    - IV methylprednisolone (1g/day) X 3 days
    - Avonex (interferon beta-1a)

Neuroretinitis

- Unilateral vision loss in the presence of an optic neuritis and macular star
- Etiology:
  - Idiopathic (25%)
  - Cat-scratch disease (60%)
    - Bartonella henselae
  - Syphilis, Lyme disease, Sarcoid, Toxo, TB
- Affects all ages, 10-40 year olds most affected
- Symptoms:
  - Painless, usually unilateral visual loss
    - Starts gradual
    - Becomes more severe after about 1 week
  - Prior viral-like illness (50%)

Neuroretinitis

- Signs:
  - Usually unilateral:
    - Papillitis with peripapillary and macular edema
    - Macular star develops as the disc edema resolves
    - Other inflammatory signs (cell & flare, vitreous cells)
    - Parinaud's oculoglandular syndrome

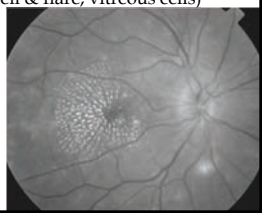

Neuroretinitis

- Diagnosis:
  - Clinical picture
  - History of cat scratch/bit/lick
  - Cat-scratch serology ELISA – very sensitive and specific
  - FTA-ABS, VDRL, Lyme titer, Toxo titer, ACE, ANA
- Treatment
  - Usually self limiting condition in immunocompetent individuals
  - Azithromycin 500 mg p.o. for 1 day, 250 mg/day X 4 days
  - Doxycycline 100 mg p.o. BID
  - Bactrim