

## Grand rounds: A string of pearls

Nathan Lighthizer, O.D., F.A.A.O.  
Assistant Professor, NSUOCO  
Chief of Specialty Care Clinics  
Chief of Electrodiagnostics Clinic  
[lighthiz@nsuok.edu](mailto:lighthiz@nsuok.edu)

## Case #1

### Recurrent Corneal Erosions (RCE's)

- Tendency for minor trauma to cause significant corneal epithelial disturbances
- Pathophysiology
  - Abnormally weak attachment between the basal cells of the corneal epithelium and their basement membrane
- Most common causes of the weak attachment
  - Mechanical trauma\*\*
  - Corneal dystrophy\*\*
  - Corneal surgery

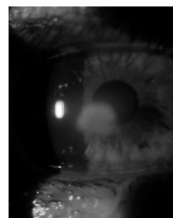
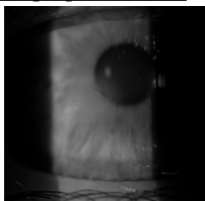
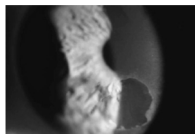
### Recurrent Corneal Erosions

- Sx's:
  - Acute, severe pain\*\*
  - Photophobia \*\*
  - Redness
  - Blepharospasm
  - Tearing

\*\*\*Usually sx's present first thing in the morning upon opening the eyes.\*\*\*  
And often this is recurrent

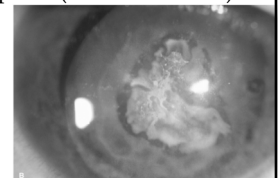
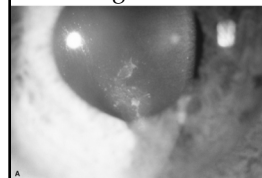
### Recurrent Corneal Erosions

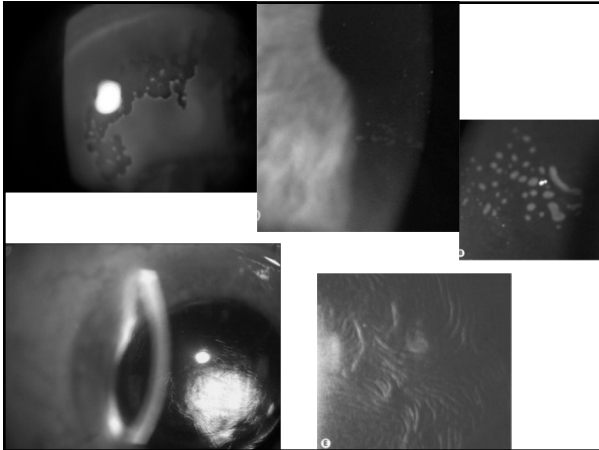
- Signs:
  - Epithelial defect may be present, usually in the inferior interpalpebral area



### Recurrent Corneal Erosions

- Signs:
  - If no defect is present, look for loose, irregular epithelium (pooling of NaFl, rapid TBUT)
  - Signs of corneal dystrophies (will be bilateral)





## Recurrent Corneal Erosions

- Tx:
  - Acutely:
    - Lubrication\*\*
    - Topical Ab (Polytrim QID, erythro or bacitracin ung)
    - Pain control:
      - Cycloplegic (Homatropine BID)
    - Muro 128 drops or ung
  - Bandage lens???
    - Alleviates pain, does not improve healing

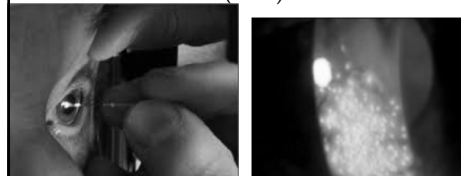## Recurrent Corneal Erosions

- Tx:
  - After the epithelium heals (recalcitrant RCE's):
    - Fresh Kote TID (15ml bottle \$25)
    - Muro 128 ung qhs (3.5g tube \$10)
    - Lotemax QID X 2 weeks, BID X 6 weeks
    - Doxycycline 20-50mg BID
      - Azasite BID (2.5ml bottle \$78)

\*\*Avoid chronic long-term AT ung\*\*

## Recurrent Corneal Erosions

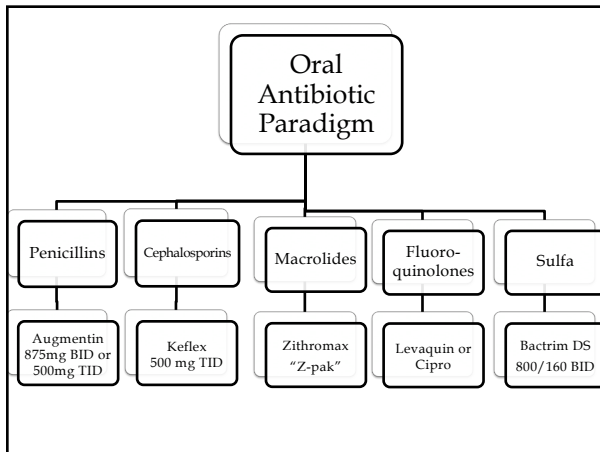
- Surgical Tx:
  - Anterior stromal micropuncture
  - Debridement of epithelium with polishing of Bowman's membrane with a diamond burr or excimer laser (PTK)



## Case #2

## Eyelid abscess vs. Preseptal Cellulitis vs. Orbital Cellulitis

- |  |  |
|--|--|
| <ul style="list-style-type: none"> <li>• Preseptal Cellulitis               <ul style="list-style-type: none"> <li>– Usually upper eyelid swelling</li> <li>– Pain, tenderness, redness</li> <li>– Usually caused by adjacent infection (hordeolum, dacryocystitis)</li> </ul> </li> </ul> | <ul style="list-style-type: none"> <li>• Orbital Cellulitis               <ul style="list-style-type: none"> <li>– All the same signs of preseptal with</li> <li>– Proptosis</li> <li>– EOM restrictions/pain with eye movements</li> <li>– Pupillary involvement</li> <li>– Usually an extension from an ethmoid sinusitis</li> </ul> </li> </ul> |
|--|--|



## Preventing Resistance

- Just one organism, methicillin-resistant *Staphylococcus aureus* (MRSA), kills more Americans every year (~19,000) than emphysema, HIV/AIDS, Parkinson's disease, and homicide combined
  - most serious MRSA infections, an estimated 85%, are associated with a healthcare exposure, but nearly 14% of the infections are community-associated
- Almost 2 million Americans per year develop hospital-acquired infections (HAIs), resulting in 99,000 deaths the vast majority of which are due to antibiotic-resistant pathogens
- CDC: *Get Smart: Know When Antibiotics Work*
  - teaches both the provider and the patient when antibiotics should be used.
- The IDSA suggests five to seven days is long enough to treat a bacterial infection without encouraging resistance in adults, though children should still get the longer course
  - this is different than previous guidelines of treating infections from 10-14 days.

10/1/18

### Ocular TRUST 3: Ongoing Longitudinal Surveillance of Antimicrobial Susceptibility in Ocular Isolates

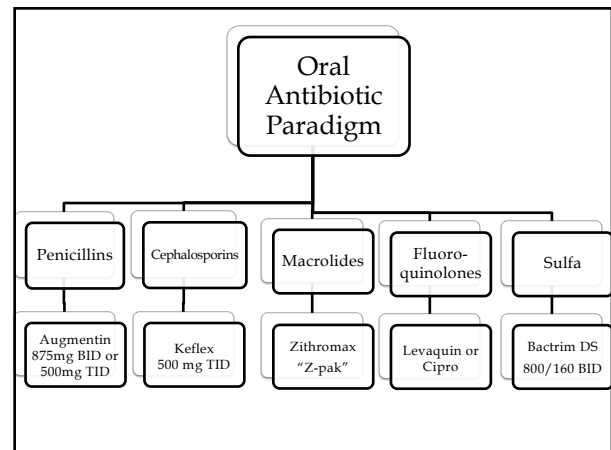
- Background:
- Ocular TRUST is an ongoing annual survey of nationwide antimicrobial susceptibility patterns of common ocular pathogens.
- To date, more than 1,000 isolates from ocular infections have been submitted to an independent, central laboratory for in vitro testing.
- Ocular TRUST, now in its third year, remains the only longitudinal nationwide susceptibility surveillance program specific to ocular isolates.

## Ocular Trust 3

- Antimicrobials tested represent six classes of drugs:
  - fluoroquinolones (ciprofloxacin, gatifloxacin, levofloxacin, moxifloxacin);
  - dihydrofolate reductase inhibitors (trimethoprim);
  - macrolides (azithromycin);
  - aminoglycosides (tobramycin);
  - polypeptides (polymyxin B); and
  - $\beta$ -lactams (penicillin).
- Staphylococci* were classified as methicillin-resistant (MRSA) or methicillin-susceptible (MSSA) based on susceptibility to oxacillin.

## Ocular Trust 3: Results

- most antimicrobials, except penicillin and polymyxin B, continue to be highly active against MSSA (azithromycin shows only moderate activity)
- with the exception of trimethoprim and tobramycin, less than one-third of MRSA strains are susceptible to ophthalmic antimicrobials
- susceptibility profiles remain virtually identical for the fluoroquinolones, regardless of methicillin phenotype
- S. aureus* is more susceptible to the fluoroquinolones than to macrolides, as represented by azithromycin



## Case #3

## Acanthamoeba keratitis

- History of CL wear w/ poor lens hygiene
- Often a history of hot tub/swimming pool/swimming in the river
- Symptoms:
  - Severe pain out of proportion to clinical picture
  - Redness & photophobia
  - All over the course of several weeks
- Signs:
  - Early -> Pseudodendrites
  - Late -> Ring-shaped stromal infiltrate

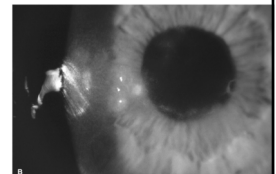
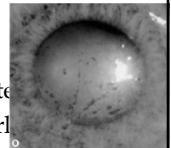
## Acanthamoeba Keratitis

- Sx's:
  - Severe pain\*\*
  - Redness
  - Tearing
  - Decreased vision
  - Photophobia
  - Minimal discharge

These sx's tend to develop over a period of weeks.\*\*  
H/O CL hygiene problems and swimming in lenses\*\*

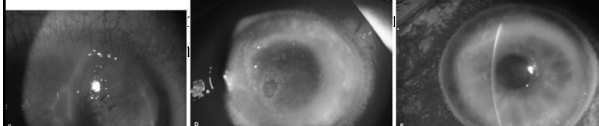
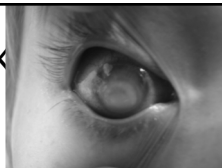
## Acanthamoeba Keratitis

- Signs:
  - Epithelial or subepithelial infiltrates appearing as pseudodendrites early
  - Patchy anterior stromal infiltrates can also appear early



## Acanthamoeba k

- Signs:
  - Radial keratoneuritis\*\*
    - Perineural infiltrates seen during the first 1-4 weeks
  - Gradual enlargement and coalescence of the infiltrates to form a ring infiltrate\*\*
    - Inflammation in the cornea doesn't look that bad\*\*



## Acanthamoeba Keratitis

- Tx:
  - Topicals:
    - PHMB 0.02% drops q1h
    - Chlorhexidine 0.02% q1h
      - Fine line agents can be given separately or together
    - Propamidine 1% (Brolene) q1h
  - Orals:
    - Voriconazole 200 mg BID
    - Itraconazole 200-400 mg QD
  - Cycloplegics (homatropine BID)
  - Topical steroids??
  - Pain control
  - Surgery

## Fungal keratitis

- Often a history of vegetative trauma, CL wear
- H/O poor response to topical Ab's
- Symptoms:
  - Pain, photophobia, tearing, FB sensation
    - Pain often less than what the clinical picture would indicate
- Signs:
  - Stromal infiltrate w/ a feathery border
  - Satellite lesions surrounding the primary infiltrate

## Fungal Keratitis

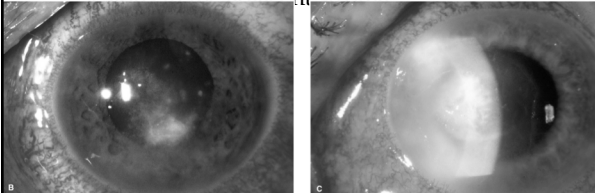
- Sx's:
  - Gradual onset of pain
  - Irritation/grittiness
  - Photophobia
  - Blurred vision
  - Watery or mucopurulent discharge

H/O cornea infection diagnosed as bacterial\*\*

H/O vegetative trauma, CL abuse, chronic steroid use

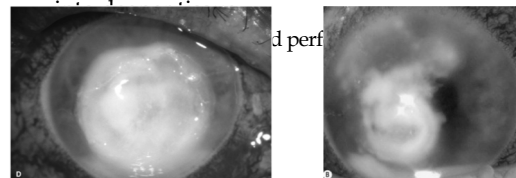
## Fungal Keratitis

- Signs:
  - Gray-white stromal infiltrate with indistinct "fluffy" or "feathery" borders/margins
  - Often surrounded by fingerlike satellite lesions in the adjacent stroma



## Fungal Keratitis

- Signs:
  - Epithelial defect overlying the ulcer
    - However can be quite small and sometimes is not present
  - Infiltrates may progressively enlarge and extend



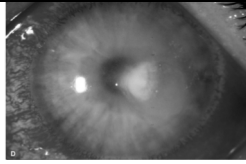
## Fungal Keratitis

- Tx:
  - Pts may require hospitalization
  - Topical meds:
    - Natamycin 5% (for filamentous fungi)\*
    - Amphotericin B 0.15% (for Candida)\*
    - Both q1h around the clock initially and then tapered over 6-12 weeks
  - Orals meds:
    - Voriconazole 200 mg BID
    - Itraconazole
    - Fluconazole
  - Cycloplegics (homatropine BID)
  - Surgical (PKP or DALK)

Which topical antibiotic is your "go-to" choice for a suspected MRSA infectious bacterial ulcer?

- A. Zymaxid/Zymar
- B. Polytrim
- C. Besivance
- D. Moxeza/Vigamox
- E. Ciloxan
- F. Tobramycin
- G. Vancomycin

## Bacterial Ke

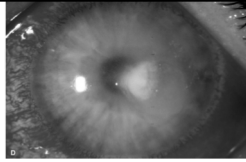


- Tx:
  - Hospitalization???
  - No CL's\*\*\*
  - Pain relief
  - Topical Ab's: (amount & strength depends on the ulcer)
    - Besivance, Moxeza, or Zymarid q1h around the clock for 24-48 hours & tapering according to clinical progress
    - Besivance (or Moxeza or Zymarid) & Tobramycin (or Gentamicin) q1h alternating around the clock
  - Fortified Ab's??? (large ulcers, visual axis, hypopyon)
    - Fortified Vancomycin, cephalosporins and/or gentamicin

## Ocular Trust 3: Results

- most antimicrobials, except penicillin and polymyxin B, continue to be highly active against MSSA (azithromycin shows only moderate activity)
- with the exception of trimethoprim and tobramycin, less than one-third of MRSA strains are susceptible to ophthalmic antimicrobials
- susceptibility profiles remain virtually identical for the fluoroquinolones, regardless of methicillin phenotype
- S. aureus is more susceptible to the fluoroquinolones than to macrolides, as represented by azithromycin

## Bacterial Ke



- Tx:
  - Steroids???
    - Reduce inflammation, improve comfort, and minimize corneal scarring...but evidence that they improve final visual outcome is limited
    - Will make herpes, fungal, acanth much worse
    - Epithelialization may be slowed by steroids
    - Can cause corneal thinning (but not usually)
    - DO NOT USE until clinical improvement is seen with Ab's alone
    - Pred Forte QID
  - Doxycycline or Azasite???
    - Inhibit MMP-9

## Case #4

## Scleritis

- Rare disorder of inflammation & necrosis centered on the sclera
- 30-60 year olds, female > male
- Bilateral 40-80% of time
- Pathophysiology is poorly understood
- Etiology
  - 50% of cases are idiopathic
  - 50% of cases are associated with systemic disease
    - Connective tissue diseases
      - RA most common
    - Infections
      - HZO, HSK, syphilis

## Scleritis

- Types of Scleritis
  1. Diffuse anterior scleritis
  2. Nodular anterior scleritis
  3. Necrotizing anterior scleritis w/ inflammation
  4. Necrotizing anterior scleritis w/o inflammation (scleromalacia perforans)
  5. Posterior scleritis

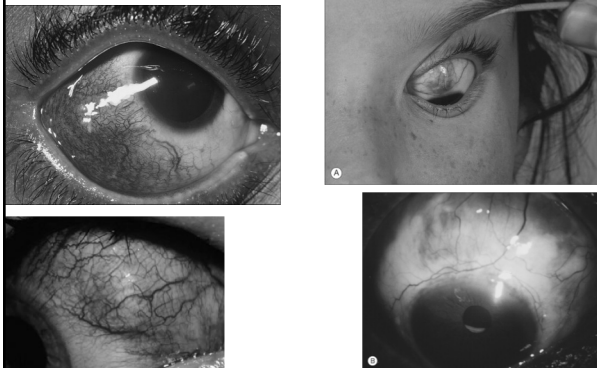
## Scleritis

- Symptoms
  - Severe, boring, deep eye pain\*\*\* (80%)
    - Can radiate to the forehead, brow, jaw
    - May awaken pt from sleep
  - Diffuse red eye
  - Photophobia
  - Tearing

## Scleritis

- Signs
  - Sectoral or diffuse inflammation of conj, episcleral, and scleral vessels
    - Scleral vessels do not move at all and do not blanch w/ phenyl
  - Bluish hue to sclera\*\*\*
  - Scleral nodules
  - Corneal changes (peripheral infiltrates/keratitis)

## Scleritis



## Scleritis

- Differential Diagnosis
  - Episcleritis
  - Uveitis
- Diagnosis
  - Clinical picture
  - If underlying systemic disease is not known, systemic workup is indicated (refer to PCP or internist)\*\*\*
    - CBC
    - ANA/Rf/HLA-B27
    - ESR
    - RPR/FTA-ABS
    - Fasting blood sugar
    - ACE
    - C-ANCA, P-ANCA

## Scleritis

- Treatment – depends on severity and type
  - Oral NSAIDs
    - Indomethacin 25-50 mg TID
    - Ibuprofen 400-600 mg QID
    - Naproxen 250-500 mg BID
  - Oral Steroids
    - Prednisone 60-100 mg QD X 1 week with taper down to 20 mg QD over next 2-3 weeks, slow taper after that as well
  - Immunosuppressive therapy
    - Cyclophosphamide, methotrexate, cyclosporin

## Herpes Zoster

- Nearly 1 million Americans develop shingles each year
- Ocular involvement accounts for up to 25% of presenting cases
- Over 50% incur long term ocular damage

## Herpes Zoster

\*\*\*Varicella-Zoster Virus\*\*\*

- Herpes DNA virus that causes 2 distinct syndromes
  1. Primary infection – Chicken pox (Varicella)
    - Usually in children
    - Highly contagious\*\*\*
    - Very itchy maculopapular rash with vesicles that crust over after  $\approx$  5 days
    - 96% of people develop by 20 years of age
    - Vaccine now available

## Herpes Zoster

- Herpes DNA virus that causes 2 distinct syndromes
  2. Reactivation – Shingles (Herpes Zoster)
    - More often in the elderly and immunosuppressed (AIDS)
      - Systemic work-up if Zoster in someone < 40
    - Can get shingles anywhere on the body
    - Herpes Zoster Ophthalmicus (HZO)
      - Shingles involving the dermatome supplied by the ophthalmic division of the CNV (trigeminal)
        - » 15% of zoster cases

## Herpes Zoster

- Symptoms:
  - Generalized malaise, tiredness, fever
  - Headache, tenderness, paresthesias (tingling), and pain on one side of the scalp\*\*\*
    - Will often precede rash
  - Rash on one side of the forehead
  - Red eye
  - Eye pain & light sensitivity

## Herpes Zoster

- Signs:
  - Maculopapular rash -> vesicles -> pustules -> crusting on the forehead
  - Respects the midline\*\*\*
  - Hutchinson sign
    - rash on the tip or side of the nose\*\*\*
  - Classically does not involve the lower lid
  - Numerous other ocular signs

## Herpes Zoster

- Other Eye Disease (Acute):
  - Acute epithelial keratitis (pseudodendrites)
  - Conjunctivitis
  - Stromal (interstitial) interstitial keratitis
  - Endotheliitis (disciform keratitis)
  - Neurotrophic keratitis

## Herpes Zoster

- Other Eye Disease (Acute):
  - Episcleritis
  - Scleritis
  - Anterior uveitis
  - IOP elevation
  - Retinitis
  - Choroiditis
  - Neurological complications (nerve palsies)
  - Vascular occlusion



– Treat the complications just like as if they were

## Herpes Zoster

- Treatment:
  - Treat the complications just like as if they were primary conditions
  - Oral antivirals – must be started within 72 hours of symptoms\*\*
    - Acyclovir 800mg 5x/day x 7-10 days
    - Valtrex 1000mg 3x/day X 7-10 days
    - Famciclovir 500mg 3x/day X 7-10 days
  - Topical ointment to skin lesions to help prevent scarring
    - Bacitracin, erythromycin

## Herpes Zoster

- Prevention:
  - Zostivax vaccine
    - Live attenuated herpes virus
    - Only given to people who know they had chicken pox as a child\*\*\*
    - Only studied in patients > 60 yo
      - 51% reduction in incidence of HZ
      - 60% reduction in symptom severity in those who got HZ
      - 66.5% reduction in post-herpetic neuralgia

## Shingrix Vaccine

- Shingrix is a non-live vaccine given intramuscularly in two doses.
- 38,000 patients in a phase III clinical trial
  - >90% efficacy sustained over 4 years

## Shingrix vs. Zostivax

- Shingrix:
  - Efficacy in preventing shingles:
    - 96.6% effective in 50-59 year olds
    - 97.4% effective in 60-69 year olds
    - > 70 year olds
      - 97.6% in year 1
      - 84.7% in years 2-4
  - Efficacy in preventing PHN
    - 91.2% in > 50 year olds
    - 88.8% in > 70 year olds
- More cost effective
- Lasts longer

- ▣ Zostivax:
  - Efficacy in preventing shingles:
    - 70% effective in 50-59 year olds
    - 64% effective in 60-69 year olds
    - > 70 year olds
      - ▣ 38%
  - Efficacy in preventing PHN
    - ▣ 65.7% in 60-69 year olds
    - ▣ 66.8% in > 70 year olds

**RZV use in immunocompetent adults aged ≥50 years.** With high efficacy among adults aged ≥50 years, and modest waning of protection over 4 years following vaccination, RZV has the potential to prevent substantial herpes zoster disease burden. Vaccinating adults starting at age 50 will prevent disease incidence in midlife, and the vaccine will likely continue to provide substantial protection beyond 4 years as recipients age.

**RZV use in immunocompetent adults who previously received ZVL.** In separate clinical trials, RZV estimates of efficacy against herpes zoster were higher than ZVL estimates in all age categories. The difference in efficacy between the two vaccines was most pronounced among recipients aged ≥70 years. Studies have shown that ZVL effectiveness wanes substantially over time, leaving recipients with reduced protection against herpes zoster. RZV elicited similar safety, reactogenicity, and immunogenicity profiles regardless of prior ZVL receipt; therefore, ZVL recipients will likely benefit from vaccination with RZV.

**Current herpes zoster infection.** RZV is not a treatment for herpes zoster or postherpetic neuralgia and should not be administered during an acute episode of herpes zoster.

**Pregnancy and breastfeeding.** There are no available data to establish whether RZV is safe in pregnant or lactating women and there is currently no ACIP recommendation for RZV use in this population. Consider delaying vaccination with RZV in such circumstances.

**General use.** RZV may be used in adults aged ≥50 years, irrespective of prior receipt of varicella vaccine or ZVL, and does not require screening for a history of chickenpox (varicella). ZVL remains a recommended vaccine for prevention of herpes zoster in immunocompetent adults aged ≥50 years (6). Care should be taken not to confuse ZVL, which is stored in the freezer and administered subcutaneously, with RZV, which is stored in the refrigerator and administered intramuscularly.

**Dosing schedule.** Following the first dose of RZV, the second dose should be given 2–6 months later (1). The vaccine series need not be restarted if more than 6 months have elapsed since the first dose; however, the efficacy of alternative dosing regimens has not been evaluated, data regarding the safety of alternative regimens are limited (30), and individuals might remain at risk for herpes zoster during a longer than recommended interval between doses 1 and 2. If the second dose of RZV is given less than 4 weeks after the first, the second dose should be repeated. Two doses of the vaccine are necessary regardless of prior history of herpes zoster or prior receipt of ZVL.

**Timing of RZV for persons previously vaccinated with ZVL.** Age and time since receipt of ZVL may be considered to determine when to vaccinate with RZV. Studies examined the safety and immunogenicity of RZV vaccination administered ≥5 years after ZVL (21); shorter intervals have not been studied. However, there are no data or theoretical concerns to indicate that RZV would be less safe or less effective when administered at an interval of <5 years. Clinical trials indicated lower efficacy of ZVL in adults aged ≥70 years; therefore, a shorter interval may be considered based on the recipient's age when ZVL was administered. Based on expert opinion, RZV should not be given <2 months after receipt of ZVL.

**Persons with a history of herpes zoster.** Herpes zoster can recur. Adults with a history of herpes zoster should receive RZV. If a patient is experiencing an episode of herpes zoster, vaccination should be delayed until the acute stage of the illness is over and symptoms abate. Studies of safety and immunogenicity of RZV in this population are ongoing.

**Persons with chronic medical conditions.** Adults with chronic medical conditions (e.g., chronic renal failure, diabetes mellitus, rheumatoid arthritis, and chronic pulmonary disease) should receive RZV.

**Immunocompromised persons.** As with ZVL, the ACIP recommends the use of RZV in persons taking low-dose immunosuppressive therapy (e.g., <20 mg/day of prednisone or equivalent or using inhaled or topical steroids) and persons anticipating immunosuppression or who have recovered from an immunocompromising illness (9). Whereas RZV is licensed for all persons aged ≥50 years, immunocompromised persons and those on moderate to high doses of immunosuppressive therapy were excluded from the efficacy studies (ZOE-50 and ZOE-70), and thus, ACIP has not made recommendations regarding the use of RZV in these patients; this topic is anticipated to be discussed at upcoming ACIP meetings as additional data become available.

**Persons known to be VZV negative.** Screening for a history of varicella (either verbally or via laboratory serology) before vaccination for herpes zoster is not recommended. However, in persons known to be VZV negative via serologic testing, ACIP guidelines for varicella vaccination should be followed. RZV has not been evaluated in persons who are VZV seronegative and the vaccine is not indicated for the prevention of chickenpox (varicella).

## Herpes Zoster

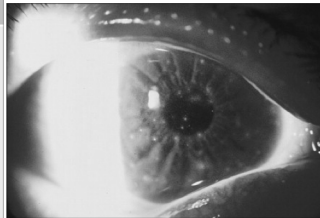

- Post-herpetic Neuralgia
  - Constant or intermittent pain that persists for more than one month after the rash has healed
  - Older patients with early severe pain and larger area are at greater risk
  - Can be so severe that it leads to depression & suicide
  - Improves with time
    - Only 2% of pts affected 5 years out
  - Tx:
    - Cool compresses

## Viral conjunctivitis

- Signs:
  - Red eye (conj hyperemia)
  - Watery discharge
  - Follicles in the inferior fornix & conj
  - (+) PA node\*\*\*
  - Red/swollen eyelids
  - Petechial sub-conj hemes
  - SPK
  - SEI's (sub-epithelial infiltrates)
  - Pseudomembranes/membranes

## EKC

- Timecourse



## Viral conjunctivitis

- Signs:
  - Red eye (conj hyperemia)
  - Watery discharge
  - Follicles in the inferior fornix & conj
  - (+) PA node\*\*\*
  - Red/swollen eyelids
  - Petechial sub-conj hemes
  - SPK
  - SEI's (sub-epithelial infiltrates)
  - Pseudomembranes/membranes

## EKC conjunctivitis

- Diagnosis
  - Based on clinical symptoms
- Treatment:
  - Cool compresses
  - Artificial tears
  - “get the red out drops”
    - Vasoconstrictors such as Visine
  - Hygiene\*\*\*
  - Quarantine/Isolation
  - Betadine 5% solution???
  - Zirgan222

## EKC conjunctivitis

- Diagnosis
  - Based on clinical symptoms
- Treatment:
  - Cool compresses
  - Artificial tears
  - “get the red out drops”
    - Vasoconstrictors such as Visine
  - Hygiene\*\*\*
  - Quarantine/Isolation
  - Betadine 5% solution???
  - Zirgan222

## Off-Label Adenoviral Treatments

- Povidone Iodine (0.4%) – Dexamethasone (0.1%)
  - 9 eyes of 6 patients with confirmed Adenovirus enrolled
  - 8/9 enrolled showed clinical resolution by day 4
  - 6/6 patients with significant reduced DNA copies by day 5
  - 5/6 cultures positives with no infectivity by day 5

## Herpes Simplex

- Most common virus found in humans
  - 60-99% are infected by 20 years old
- Double stranded DNA virus
  - HSV type 1 (HSV-1)
  - HSV type 2 (HSV-2)
- Primary infection
  - Occurs in childhood via droplet exposure
  - Subclinical infection in most
- Secondary infection (recurrence)

## Herpes Simplex

- Recurrent infection:
  - After primary infection the virus is carried to the sensory ganglion for that dermatome (trigeminal ganglion) where a latent infection is established.
  - Latent virus is incorporated in host DNA and cannot be eradicated
  - Stressors (trauma, UV light, fever, hormonal changes, finals week, etc) cause reactivation of the virus and it is transported in the sensory axons to the periphery -> clinical signs/symptoms

## Herpes Simplex Keratitis

- **Epithelial Keratitis:**
  - Symptoms:
    - Ocular irritation, redness, photophobia, watering, blurred vision
  - Signs:
    - Swollen opaque epithelial cells arranged in a coarse punctate or stellate pattern
    - Central desquamation results in a dendrite\*\*\*
      1. Central ulceration
      2. Terminal end bulbs
    - \*\*\*Corneal sensation is reduced\*\*\*

## Herpes Simplex Keratitis

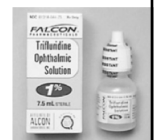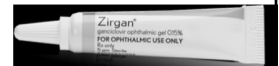
- **Epithelial Keratitis:**
  - Symptoms:
    - Ocular irritation, redness, photophobia, watering, blurred vision
  - Signs:
    - Swollen opaque epithelial cells arranged in a coarse punctate or stellate pattern
    - Central desquamation results in a dendrite\*\*\*
      1. Central ulceration
      2. Terminal end bulbs
    - \*\*\*Corneal sensation is reduced\*\*\*

## Herpes Simplex Keratitis

### • **Epithelial Keratitis:**

#### – Treatment:

- Zirgan (ganciclovir gel 0.15%)
  - 5x/day until the dendrite disappears
  - 3x/day for another week
- Viroptic (trifluridine solution 1%)
  - 9x/day until the dendrite disappears
  - 5x/day for another week
- Oral antivirals (if topical not well tolerated):
  - Acyclovir 400 mg 5x/day X 7-10 days
  - Valtrex 500 mg 3x/day X 7-10 days
  - Famvir 250 mg 3x/day X 7-10 days



## Herpes Simplex Keratitis

- **Epithelial Keratitis:**
  - Treatment (con't):
    - Debridement of the dendritic ulcer???
    - Oral antivirals???
    - IOP control
      - Avoid prostaglandins???
    - Steroids???
  - Follow-up
    - Day 1, 4, 7

## Herpes Simplex Keratitis

- **Marginal keratitis:**
  - Very rare
  - Looks like a marginal infiltrate....but
  - In HSV marginal keratitis:
    1. Much more pain
    2. Deep neovascularization
    3. No clear zone between infiltrate and limbus

## Herpes Simplex Keratitis

- **Immune Stromal Keratitis (ISK):**
  - 2% of initial ocular HSV presentations
  - 20-61% of recurrent disease
  - 88% non-necrotizing
  - 7% necrotizing
  - \*\*\*Can be visually devastating\*\*\*

## Herpes Simplex Keratitis

- **Immune Stromal Keratitis:**
  - Symptoms:
    - Gradual blurred vision
    - Halos
    - Discomfort/Pain
    - Redness

## Herpes Simplex Keratitis

- **Immune Stromal Keratitis:**
  - Signs (non-necrotizing):
    - Stromal haze (inflammation & edema)
    - Neovascularization (deep)
    - Immune ring
    - Scarring and/or thinning
    - Intact epithelium\*\*\*
  - Signs (necrotizing):
    - All of the above
    - More dense infiltration
    - Often w/ overlying epithelial defect
    - Necrosis and/or ulceration

## Herpes Simplex Keratitis

- **Immune Stromal Keratitis:**
  - Treatment:
    - Topical steroids
      - Pred Forte QID-q2H
      - Durezol BID-QID
      - Lotemax QID
    - Topical anti-viral cover
      - Viroptic (trifluridine 1%) QID
      - Zirgan (ganciclovir 0.15%) QID
    - Topical cyclosporin (Restasis), AT's, ung's to facilitate epithelial healing if ulceration is present

## Herpes Simplex Keratitis

- **Endotheliitis:** AKA Disciform Keratitis
  - Not considered a primary form of stromal keratitis
    - Stromal edema is present secondary to endothelial inflammation
  - Symptoms:
    - Blurred vision
    - Halos
    - Discomfort/Pain
    - Redness

## Herpes Simplex Keratitis

- **Endotheliitis:** AKA Disciform Keratitis
  - Signs:
    - Central zone of stromal edema often with overlying epithelial edema
    - KP's underlying the edema
    - AC reaction
    - IOP may be elevated
    - Reduced corneal sensation
    - Healed lesions often have a faint ring of stromal or subepithelial opacification and thinning

## Herpes Simplex Keratitis

- **Endotheliitis:** AKA Disciform Keratitis
  - Treatment:
    - Topical steroids
      - Pred Forte QID-q2H
      - Durezol BID-QID
      - Lotemax QID
    - Topical anti-viral cover
      - Viroptic (trifluridine 1%) QID
      - Zirgan (ganciclovir 0.15%) TID
    - Topical cyclosporin (Restasis), AT's, ung's to facilitate epithelial healing if ulceration is present

## Herpes Simplex Keratitis

- **Neurotrophic Keratitis:**
  - Keratopathy occurs from loss of trigeminal innervation to the cornea resulting in complete or partial anaesthesia
  - The cornea is numb so the pt doesn't blink
  - Sx's:
    - Irritation/burning/FB sensation
    - Redness
    - Tearing
    - Decreased vision

## Neurotrophic Keratopathy

- Signs:
  - Decreased corneal sensation\*\*\*
  - Interpalpebral SPK
  - **Persistent epithelial defects** in which the epithelium at the edge of the lesion appears rolled and thickened, and is poorly attached
  - Advanced cases may have sterile ulceration, keratitis, and/or corneal melt
    - Pt may be surprisingly asymptomatic\*\*

## Neurotrophic Keratopathy


- Tx:
  - Find out the cause
  - D/C any meds that may be responsible
  - Lubricate, lubricate, lubricate\*\*\*
    - Preservative free AT's, gels, and ung's q1h-QID
  - Topical Ab drops and/or ung (Polytrim QID, etc)
  - Taping the eyelids at night to ensure adequate closure
  - In severe cases:

## Neurotrophic Keratopathy

- Tx:
  - Healing an ulcer that won't heal
    1. Autologous serum
    2. Prokera
      - Amniotic membrane in a CL skirt
  - 1. Also could use a scleral lens

## Autologous Serum

1. Draw 40cc of blood through venipuncture
2. Centrifuge for 5 minutes @ 1500 rpm
3. Centrifuging will divide the blood into its separate components
4. Place 1cc of serum in each bottle
5. Add 4cc of saline to make a concentration of 20% serum eye drops



drop concentration

Table 1. Comparison of the biochemical properties of normal human tears and serum<sup>1,2</sup>

	Tears	Serum
pH	7.4	7.4
Osmolality	296	296
EGF (ng/ml)	0.2-3.0	0.5
TGF- $\beta$ (ng/ml)	2-10	6-33
Vitamin A (ng/ml)	0.03	46
Lysosyme (ng/ml)	1.4	6
IgA (ug/ml)	1190	2
Fibrinogen (ug/ml)	21	295

EGF = epithelial growth factor; TGF- $\beta$  = transforming growth factor

## Herpes Simplex Epithelial Keratitis

- My Regimen:
  - Zirgan 5x/day until the ulcer heals, then 3x/day for one week
  - Oral Valtrex 500 mg 3x/day for 7-10 days
  - Artificial tears
  - L-Lysine 2 grams daily?
  - Debride the ulcer?
- RTC 1 day, 4 days, 7 days

## Herpes Simplex Keratitis

- Prophylactic Treatment:
  - Reduces the rate of recurrence of epithelial and stromal keratitis by  $\approx$  50%
    - Acyclovir 400 mg BID
    - Valtrex 500 mg QD
    - Famvir 250 mg QD
  - L-lysine 1 gram/day
  - Frequent debilitating recurrences, bilateral involvement, or HSV infection in an only eye

## Pediatric HSV Keratitis

- pediatric herpes simplex keratitis has an 80% risk of recurrence, a 75% risk of stromal disease, and a 30% rate of misdiagnosis
- 80% of children with herpes simplex keratitis develop scarring, mostly in the central cornea
- –results in the development of astigmatism
- –25% of children have more than 2 D of astigmatism, most of which is irregular

## Herpes Simplex

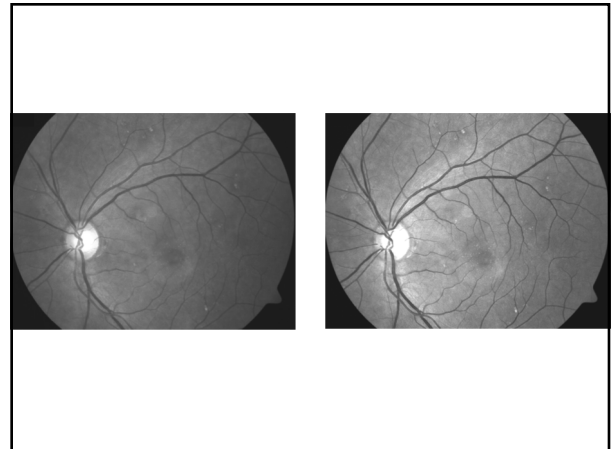
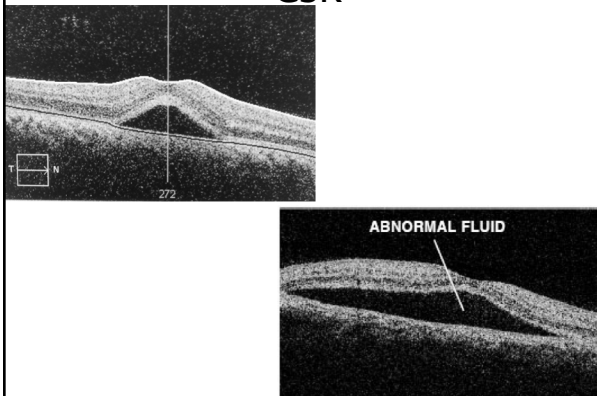
- Visual Prognosis:
  - 90% 20/40 or better after 12 years
  - 3% 20/100 or worse after 12 years

## Case #5

## Central Serous Chorioretinopathy (CSR)

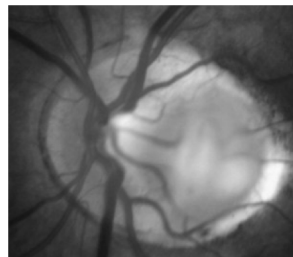
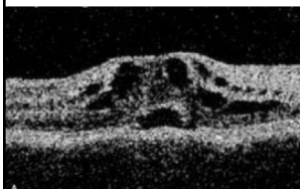
- Demographics
  - 25-50 year old men, stressed/Type A personalities
- Symptoms
  - Unilateral, blurred vision
    - VA -> usually 20/20 - 20/80
  - Metamorphopsia
- Signs
  - Localized serous detachment of the neurosensory retina in the macula

### CSR



## Central Serous Chorioretinopathy

- DDx:
  - Optic disc pit
  - CNVM



## Central Serous Chorioretinopathy

- Med associations:
  - Steroids
    - Nasal sprays, steroid creams, oral, injectable
  - Ephedra
    - Ephedrine & pseudoephedrine
- Treatment:
  - Observation/lifestyle change
  - D/C steroid if possible
  - Possible laser therapy

## Case #6

### Plaquenil Toxicity

- Antimalarials:
  - Chloroquine
  - Hydroxychloroquine (Plaquenil)
- Now used for RA, SLE, Sjogren's, etc.
- Toxicity risk is low, but....
- Lots of different screening recommendations have been proposed

### Plaquenil Toxicity

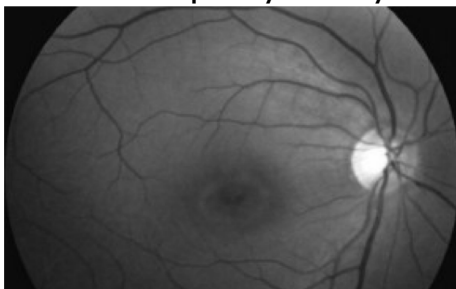
- Risk Factors:
  - Cumulative dose\*\*
    - 1000 gram cumulative dose for Plaquenil
    - 6.85 years to reach that
  - Daily dose
  - Age
  - Liver or kidney dysfunction
  - Pre-existing retinal disease or maculopathy

### Plaquenil Toxicity

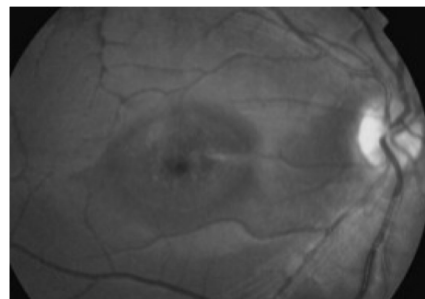
- Symptoms:
  - Asymptomatic early
  - Paracentral visual field defects affecting reading
  - Color vision changes
- Signs:



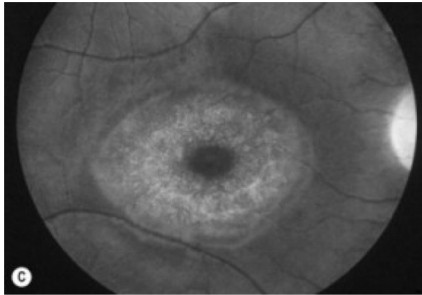
### Progression of Plaquenil maculopathy - early



### Progression of Plaquenil maculopathy - moderate

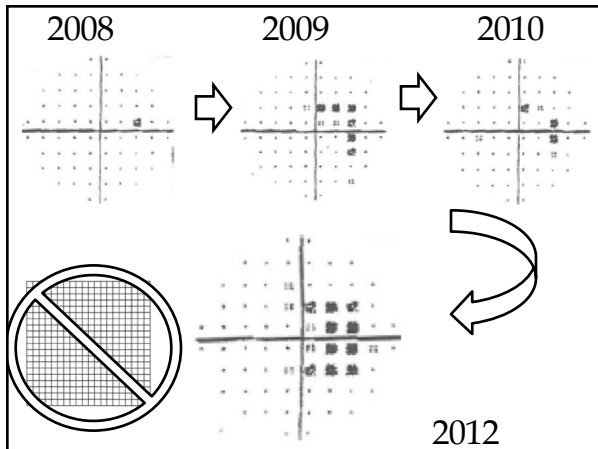


## Progression of Plaquenil maculopathy - advanced



## Plaquenil Toxicity

- Recommended Screening Guidelines:
  1. Baseline exam within the first year of starting Plaquenil
    - Biomicroscopy exam, 10-2 VF, Fundus photos
- After 5 years, annual screening exams
  - SD-OCT or
  - mfERG or
  - Fundus autofluorescence



## Plaquenil Toxicity

- Recommended Screening Guidelines:
  1. Baseline exam within the first year of starting Plaquenil
    - Biomicroscopy exam, 10-2 VF, Fundus photos
    - SD-OCT or mfERG or fundus autofluorescence
- After 5 years, annual screening exams
  - Biomicroscopy exam along with 10-2 VF and
  - SD-OCT or
  - mfERG or
  - Fundus autofluorescence

## Fundus Autofluorescence & mfERG



## Plaquenil Toxicity

- Tests not recommended for screening
  - Fundus photography
  - Time-domain OCT
  - FA
  - Full-field ERG
  - EOG
  - Color vision testing
  - Amsler grid

## Plaquenil Toxicity

- Treatment:
  - No medical therapy is available to treat/cure the toxicity
  - D/C the med if possible
    - Work with the PCP

## Case #7

## Pseudotumor Cerebri

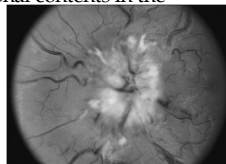- AKA
  - Idiopathic intracranial hypertension
- Elevated intracranial pressure
  - Not caused by tumor, infection, or obstruction of the ventricular system
  - Increased production vs. decreased absorption
- Etiology:
  - Idiopathic (young, obese females)
  - Medications
    - Oral contraceptives, Tetracyclines, too much vitamin A
  - Trauma

## Pseudotumor Cerebri

- Symptoms:
  - HA's (90%)
  - Visual disturbances (72%)
    - Transient visual obscurations (TVO's)
  - Tinnitus (60%)
  - Diplopia (20%)
  - Blurred vision
  - Abnormal color vision
  - N&V

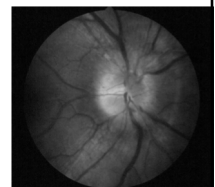## Pseudotumor Cerebri

- Signs
  - Papilledema – hallmark sign of PTC
    - Increased intracranial pressure -> slowing axonal transport -> accumulation of axonal contents in the NFL -> elevated ONH's
  - Bilateral disc edema
  - Blurred disc margins
  - Obscuration of blood vessels\*
  - Hyperemia of the disc
  - Venous dilation
  - Peripapillary hemorrhages & CWS



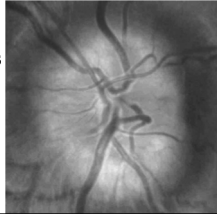
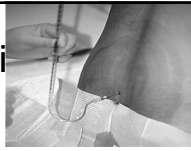## Pseudotumor Cerebri

- Other signs
  - Enlarged blind spot
  - 6<sup>th</sup> nerve palsy
    - Tends to subside as treatment is effective



## Pseudotumor Cerebri

- Diagnosis:
  - Clean MRI/MRV
  - Lumbar puncture
    - Elevated ICP > 250mmH<sub>2</sub>O in an obese pt
    - > 200mmH<sub>2</sub>O in a non-obese pt
    - Normal CSF composition
  - No other neurological findings
    - Exception -> 6<sup>th</sup> nerve palsy
  - SVP
    - Yes -> not Pseudotumor
    - No -> ?????



## Pseudotumor Cerebri

- Treatment:
  - Weight Loss\*
    - Papilledema resolution with weight loss of 6% of total body weight
  - Diamox (acetazolamide)
    - 500 mg Sequels BID-QID
    - Taper as the sx's stabilize
  - Lumbar-peritoneal shunt
  - Optic nerve sheath decompression

Thank you for your  
attention!